



# Recognizing Early Motor Delays

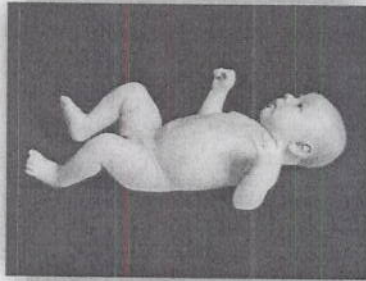## A Comparison Examination of 2 Month Old Infants

### Typical

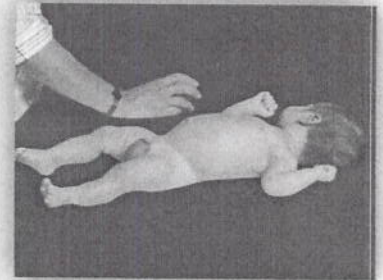
### Atypical

#### Supine

- Maintains head in midline for brief periods
- Locates objects visually and tracks from left to right
- Begins to show antigravity movements of upper and lower extremities
- Not yet able to reach and grasp toys

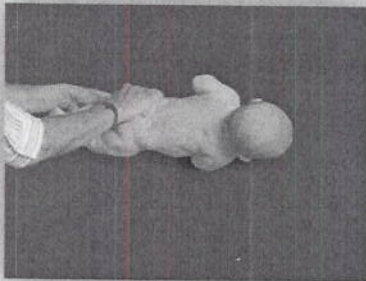


- May show more asymmetrical movement with predominance of head to one side; or strong asymmetrical tonic neck reflex (ATNR)
- Difficulty visually tracking, may only track to one side or only to midline
- Decreased ability to generate upper and lower extremity antigravity movements
- Longer periods of inactivity

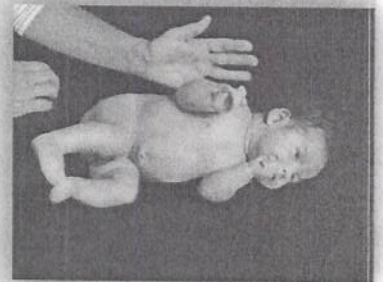


#### Sidelying

- Able to lift head and upper trunk during facilitated roll, showing lateral headrighting
- Begins to balance activity of trunk flexor and extensor muscles
- Ability to change from predominant use of flexors to use of extensors as position requires

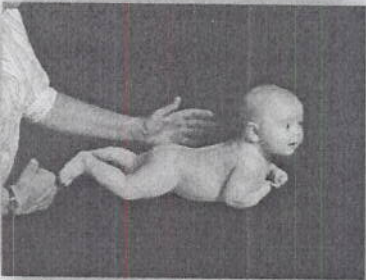


- May be unable to right head during facilitated rolling
- May look more competent in sidelying, therefore important to observe baby in all eight positions

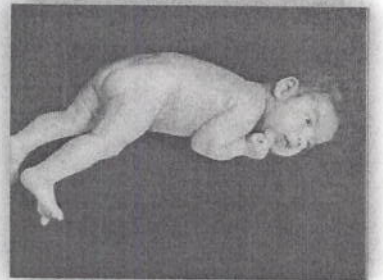


#### Prone

- Head lifting to 45 degrees and extension through upper thoracic spine
- Hips and knees begin to move from flexed "newborn" posture into extended, abducted position, which allows head and trunk lifting
- Elbows typically not directly under the shoulders until 3 months

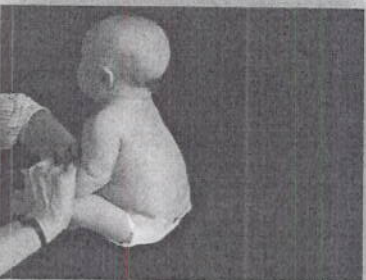


- Posture looks more like a newborn; infant does not show hip extension; hips and knees remain in flexed abducted posture.
- No independent head lifting; can move head only with assistance

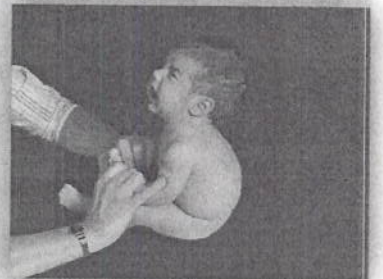

#### Pull to Sit

- Head-lag is typical until the infant is about 15 degrees from upright.
- Uses shoulder elevation and elbow flexion to assist
- Able to engage neck muscles to sustain midline head control when upright
- Good extension through the cervical and upper thoracic spine



- May exhibit head-lag through the entire pull to sit maneuver.
- Poor head control when in upright sitting
- Little muscle activity in the upper extremities or cervical spine
- When upright, rounding of the thoracic and lumbar spine



# Recognizing Early Motor Delays

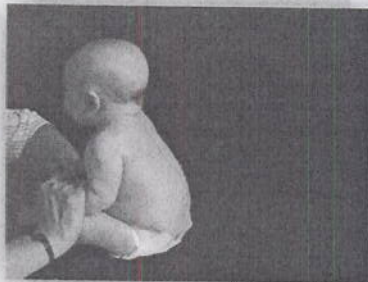## A Comparison Examination of 2 Month Old Infants

### Typical

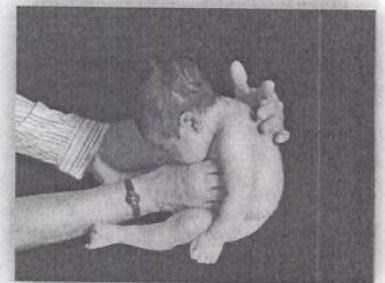
### Atypical

#### Sitting

- Head is aligned with ear directly over the shoulder
- Holds and sustains posture with assistance
- Head turning may or may not be present at 2 months, but should be seen by 3 months

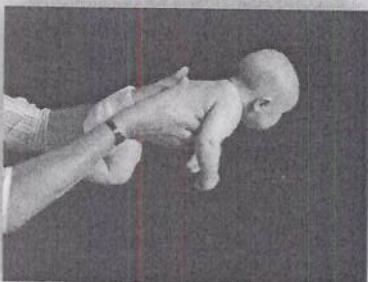


- Needs more support to sustain sitting posture
- Inability to achieve and sustain head lifting in upright position
- Little to no antigravity arm activity

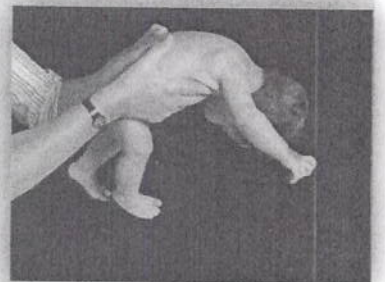


#### Horizontal Suspension

- Able to activate adequate neck and trunk extension to sustain posture
- Can maintain brief periods of head control, but may not be able to hold the head in midline

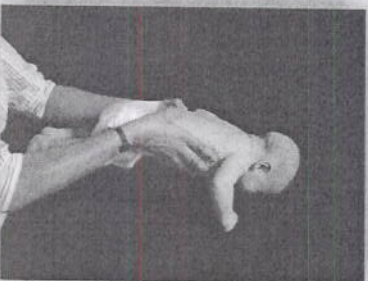


- Difficulty or inability to activate neck or upper thoracic extensors to lift head
- May try to use arm and leg movements to sustain posture

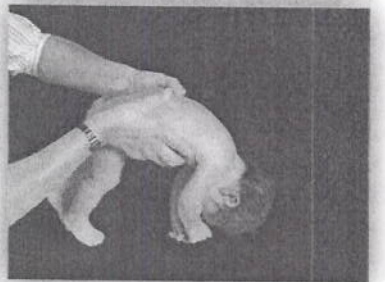


#### Protective Extension

- Aware of being tilted forward; increases head and neck extension
- Will not be fully able to bring arms forward for full protective response until 6 months

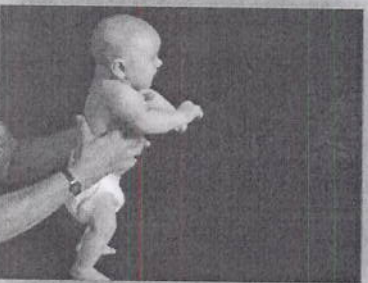


- Unable to generate antigravity head and trunk activity


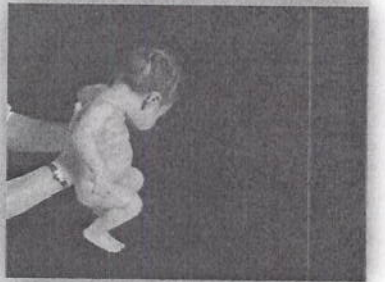


#### Standing

- Able to sustain weight on lower extremities with support at the trunk
- Typically shows intermittent bouts of extension and flexion
- Good vertical alignment from head through trunk and feet



- May support little if any weight on feet
- Little or no intermittent muscle activity to attain or maintain standing



For more information please contact  
Pathways Awareness

Toll-free (800) 955-2445 · Fax (888) 795-5884 · TTY (800) 326-8154

<http://www.pathwaysawareness.org> · [friends@pathwaysawareness.org](mailto:friends@pathwaysawareness.org)

Copy freely, do not change. Must acknowledge Pathways Awareness.



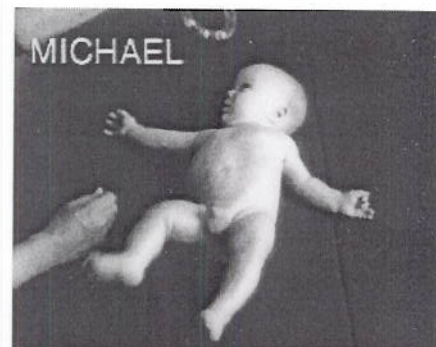

**Early Infant Assessment Redefined**  
**Comparison Examination of two six-month old infants**

**NORMAL**

**ATYPICAL**

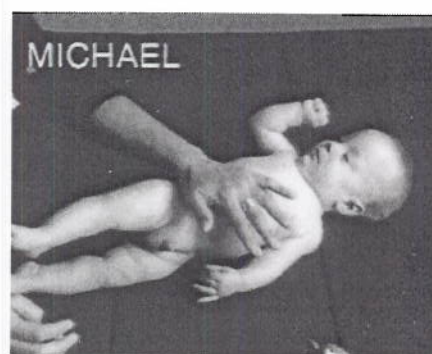

**SUPINE**

- Visual Tracking of 180°
- Head in Midline
- Reach and Grasp
- Anti-gravity Movement
- Pelvic Lifting





**LYING ON SIDE**

- Head in Midline
- Arms in Midline
- Muscle Balance
- Muscle Activation
- Weight Shifting
- Lateral Righting



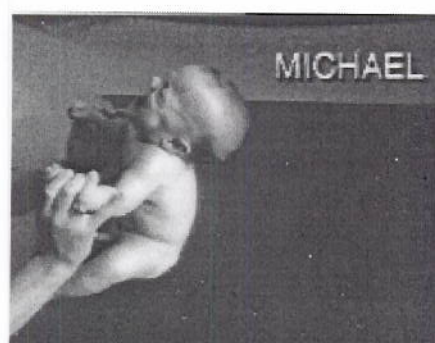
**PRONE**

- Head and Trunk Lifting
- Forward Reach
- Strong Hip Extension
- Lateral Weight Shift



**PULL TO SIT**

- Leads with Head
- Forward Flexion of Head
- Shoulder Stability
- Abdominal Activity



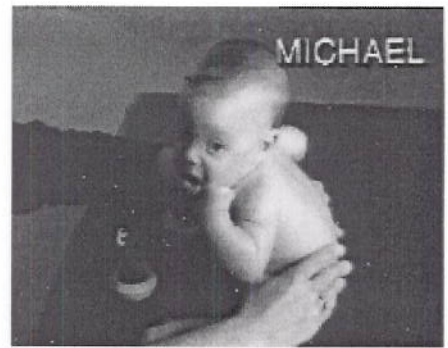

Copy Freely, Do Not Change, Must Acknowledge  
 "Pathways Awareness"

## NORMAL

## ATYPICAL



### SITTING

- Head in Midline
- Actively Leans Forward
- Reach and Grasp
- Good Back Extension



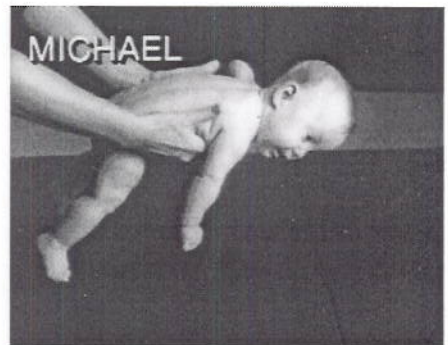
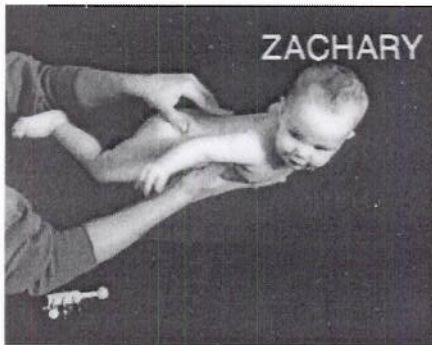
### STANDING

- Postural Alignment
- Free Movement of Arms
- Hip Extension
- Leg Mobility
- Weight Bearing on Flat Feet



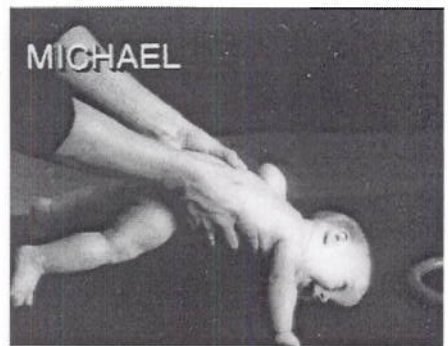
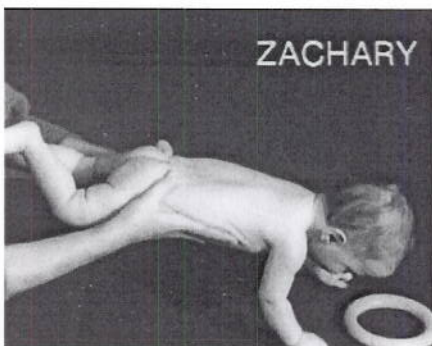
### HORIZONTAL SUSPENSION

- Anti-Gravity Movements
- Anti-Gravity Extensions
- Variety of Upper and Lower Extremity Movements



### PROTECTIVE EXTENSION

- Head in Midline
- Forward Movement of Arms
- Anti-Gravity Alignment



For more information please contact  
Pathways Awareness

Toll-free 800-955-2445 ~ Fax 888-795-5884 ~ TTY 800-326-8154  
[www.pathwaysawareness.org](http://www.pathwaysawareness.org) ~ e-mail: [friends@pathwaysawareness.org](mailto:friends@pathwaysawareness.org)

Copy Freely, Do Not Change, Must Acknowledge  
"Pathways Awareness"

